

PATIENT

Milkshake Stark

PRESENTING CLINICAL SIGNS

History: Episodes of collapse. Brief echo nsf (EL).
Current medications: Tussigon and Temaril P

SPECIES

Canine

BREED

Chihuahua Mix

SEX

Male Neutered

AGE

15 years

WEIGHT

6.2

HOLTER MONITOR FINDINGS AND RHYTHM ASSESSMENT

Time analyzed	23:40h
Mean heart rate	99bpm
Maximum heart rate	245bpm
Minimum heart rate	38bpm
VPCs	1
APCs	None

Interpretation: Underlying normal sinus rhythm with appropriate rate variation. A single VPC is identified; clinically insignificant. Two episodes of collapse are reported on the diary; 9:40pm and 11:50pm. Normal sinus rhythm documented; HR 176bpm.

Rhythm diagnosis: Sinus rhythm with a single VPC.

RECOMMENDATIONS

Apparently normal recording. No significant pauses are noted, and no malignant arrhythmias identified. The max HR appears sinus in origin, without obvious SVT or VT. A single VPC is of little consequence, and no follow up is advised.

INTERPRETED BY

Maggie Machen Lamy,
DVM, DACVIM
(Cardiology)

Most importantly, the patient experienced two collapse episodes with the monitor in place and no significant arrhythmia are identified. A normal sinus tachycardia is a secondary response rather than being a primary cause. Given these findings and the atypical signalment, arrhythmogenic syncope is highly unlikely and **other possibilities should be considered such as a musculoskeletal abnormality, BP swings, etc.** It is important to note that many cases of syncope go undiagnosed in small animals, despite thorough evaluation.

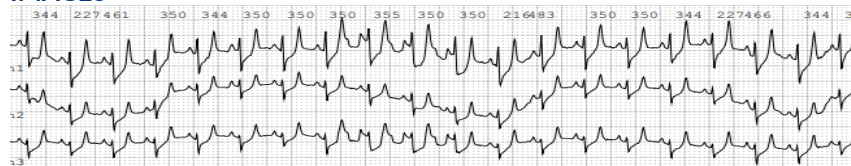
IMAGING PERFORMED BY

No medications are indicated at this time.

HOSPITAL NAME

Franklin Lakes AH

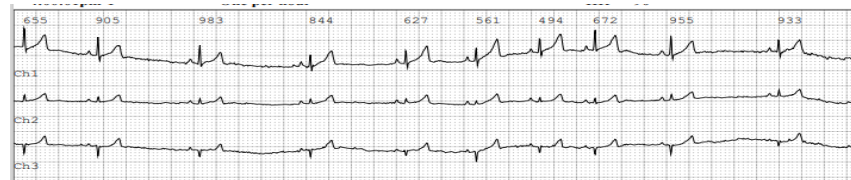
IMAGES



Recording during event

REFERRING VET

Dr. Ward



NSR

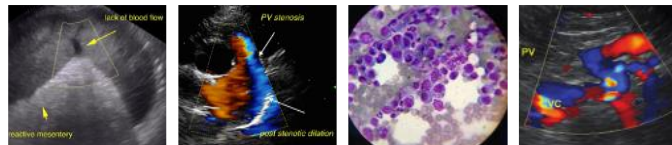
INVOICE

24120

The information and recommendations provided are based on the images presented by the referring veterinarian. No evaluation can be communicated regarding pathology that was not visible in the image/video clips provided.

DATE

5/10/22



PATIENT

Milkshake Stark

SPECIES

Canine

BREED

Chihuahua Mix

SEX

Male Neutered

AGE

15 years

WEIGHT

6.2

INTERPRETED BY

Maggie Machen Lamy,
DVM, DACVIM
(Cardiology)

**IMAGING
PERFORMED BY**

HOSPITAL NAME

Franklin Lakes AH

REFERRING VET

Dr. Ward

INVOICE

24120

DATE

5/10/22

Thank you for this referral. If the clinical or image interpretation does not parallel your findings or if I can be of any further assistance please contact me.

Maggie Machen Lamy, DVM
Diplomate of the American College of Veterinary Internal Medicine (Cardiology)
info@sonopath.com